

## P 1-12

### **Synergic regenerative effects of PDRN and microcurrent on full-thickness rotator cuff tear in rabbit**

Dong Rak Kwon<sup>1†</sup>, Gi Young Park<sup>1</sup>, Yong Suk Moon<sup>2</sup>, In Ho Woo<sup>1\*</sup>

Daegu Catholic University Medical Center, Department of Rehabilitation Medicine<sup>1</sup>,  
Daegu Catholic University Medical Center, Department of Anatomy<sup>2</sup>

#### **Objective**

The aim of this study was to investigate regenerative effects of ultrasound (US)-guided injection with polydeoxyribonucleotide (PDRN) injection with micocurrent therapy (MT) in a chronic traumatic full thickness rotator cuff tendon tear (FTRCTT) in a rabbit model.

#### **Methods**

Rabbits (n = 24) were allocated into 3 groups. After a 5-mm sized FTRCTT just proximal to the insertion site on the subscapularis tendon was created by excision, the wound was immediately covered by silicone tube to prevent natural healing. After 6 weeks, 3 different treatment regimens (0.2 mL normal saline, G1-SAL; 0.2 mL PDRN with Sham MT, G2-PDRN+ShamMT, ShamMT; 0.2 mL PDRN with MT, G3-PDRN+MT) were performed into FTRCTT under US guidance. G2-PDRN+SHAMMT+Sham MT was injected with 0.2mL PDRN, weekly four injections and sham MT for 4 weeks after the first PDRN injection. G3-PDRN+MT was injected with 0.2mL PDRN, weekly four injection and MT was applied daily for 1 hours for 4weeks. We evaluated gross morphologic changes on all rabbits after sacrifice. Proliferating cell nuclear antigen, vascular endothelial growth factor and platelet endothelial cell adhesion molecule stain were performed to evaluate histological changes. Motion analysis was also performed.

#### **Results**

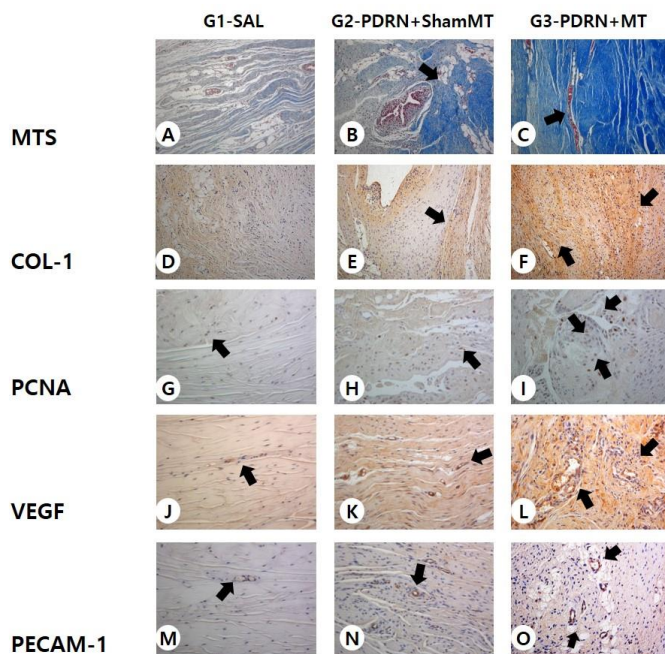
The gross morphologic mean tendon tear size in G3-PDRN+MT was significantly smaller than that of G1-SAL and G2-PDRN+SHAMMT+Sham MT ( $p < .05$ ). In G3- PDRN+MT, regenerated collagen type 1 fibers, angiogenesis, walking distance, fast walking time, and mean walking speed were greater than in the other two groups on histological examination and motion analysis.

#### **Conclusions**

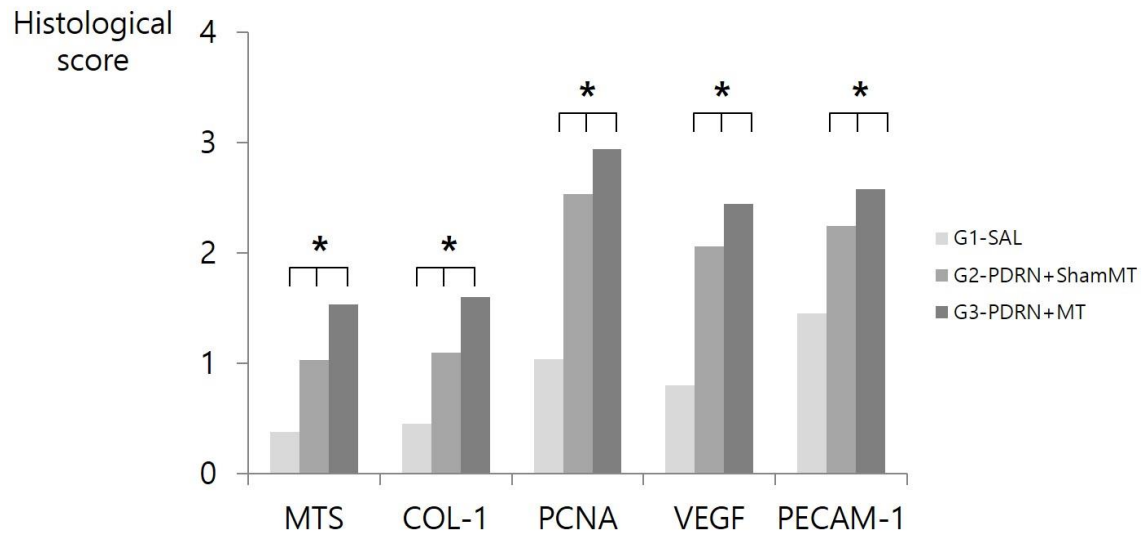
Combined therapy of PDRN with MT was more effective than PDRN alone in gross morphologic, histological and motion analysis in a rabbit model of chronic traumatic FTRCTT.

Groups (Injection regimens)			
	G1-SAL (n=8)	G2-PDRN+ShamMT (n=8)	G3-PDRN+MT (n=8)
Gross			
Tear size	15.93±2.33	12.42±1.63 <sup>*</sup>	8.78±3.54 <sup>††</sup>
Histological score			
MTS	0.38±0.49	0.98±0.86 <sup>§</sup>	1.53±0.93 <sup>¶¶</sup>
Anti-type collagen 1	0.45±0.6	1.1±0.74 <sup>§</sup>	1.6±0.8 <sup>¶¶</sup>
PCNA	1.04±0.91	2.53±0.95 <sup>*</sup>	2.94±0.81 <sup>††</sup>
VEGF	0.8±0.82	2.06±0.81 <sup>*</sup>	2.44±0.73 <sup>††</sup>
PECAM-1	1.45±1.06	2.24±0.7 <sup>*</sup>	2.58±0.71 <sup>††</sup>
Motion analysis			
Walking distance(cm)	4852.75±137.27	5514.38±257.25 <sup>*</sup>	6391.38±196.94 <sup>††</sup>
Fast walking time(%)	5.62±1.42	7.97±0.82 <sup>*</sup>	10.94±1.14 <sup>††</sup>
Mean walking speed(cm/sec)	6.3±0.57	8.21±0.58 <sup>*</sup>	11.98±1.47 <sup>††</sup>

The proportion of positive cells of PCNA, VEGF, PECAM-1 was scored as 0 = no cells stained positive, 1 = between 1% and 10%, 2 = between 11% and 33%, 3 = between 34% and 66%, and 4 = between 67% and 100%. PDRN, Polydeoxyribonucleotide; ESWT, Extracorporeal shockwave therapy; MIC, Microcurrent therapy; PCNA, proliferating cell nuclear antigen; VEGF, Vascular endothelial growth factor; PECAM-1, Platelet endothelial cell adhesion molecule.



Immunohistochemical (A-O) findings of the subscapularis tendons in G1-SAL, G2-PDRN+SHAMMT, and G3-PDRN+MT. Newly regenerated tendons are shown in the blue-stained fibers (black arrow; Masson's trichrome stain; X200) in G2-PDRN+ShamMT, and G3-PDRN+MT. Few regenerative collagen fibers were seen in G1-SAL. (A-C) Regenerated tendon fibers (black arrow; X200) were stained with anti-type 1 collagen antibody in G2-PDRN+ShamMT, and G3-PDRN+MT. Few regenerated tendon fibers were seen in G1-SAL. (D-F) Numerous PCNA stained cells (black arrow, X200) were observed in regenerated tendon fibers in G2-PDRN+ShamMT, and G3-PDRN+MT. Few PCNA stained cells were observed in G1-SAL (G-I) Numerous VEGF-positive cells and PECAM-1 positive microvascular densities (black arrows, X200) were observed in G2-PDRN+ShamMT, and G3-PDRN+MT. Few VEGF-positive cells and PECAM-1 positive microvascular densities were observed in group G1-SAL. (M-O)



Semiquantitative score of histological findings, immunoreactivity of stain. The proportion of PCNA-, VEGF-, and PECAM-1-positive cells were scored as detailed in Materials and Methods. \*P < .05 one-way ANOVA, Turkey's post hoc test among group. Abbreviations are PDRN : polydeoxyribonucleotide; MIC : Microcurrent therapy; MTS : Masson's trichrome stain; COL-1 : Anti-type 1 collagen stain; PCNA: proliferating cell nuclear antigen; VEGF : vascular endothelial growth factor; and PECAM : platelet endothelial cell adhesion molecule.